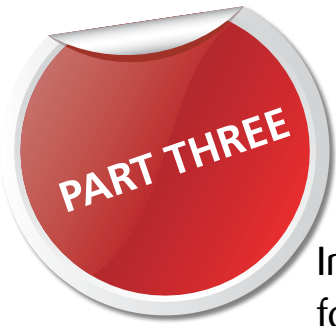



A problem shared

In part three of this series, **Liviu Steier** presents the solution he chose for last month's problem

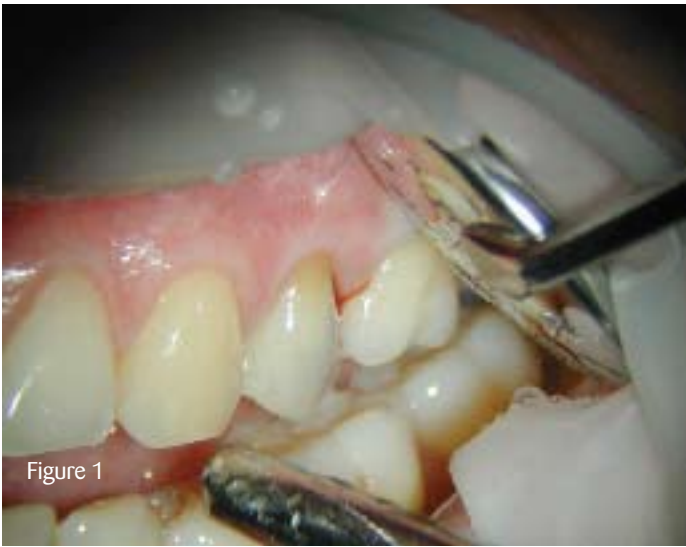

Figure 1

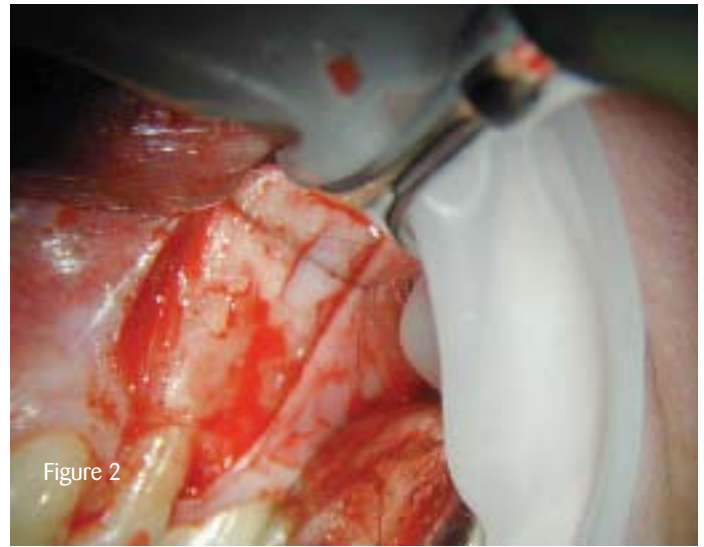


Figure 2

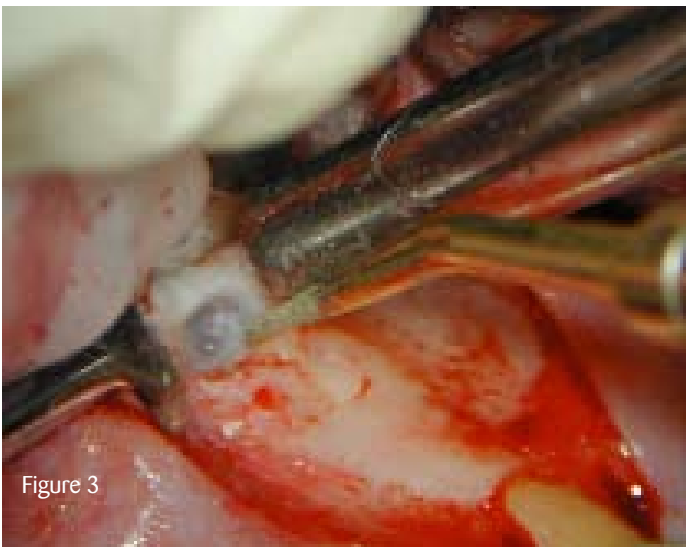

Figure 3

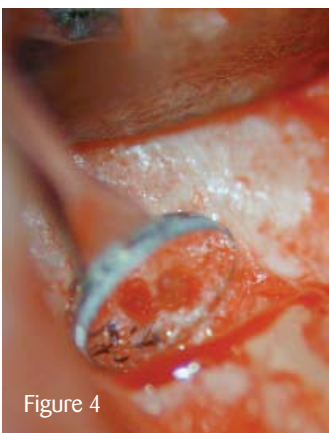


Figure 4

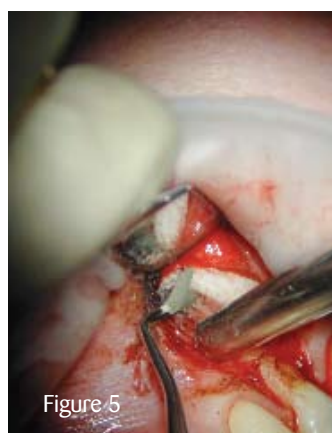

Figure 5

Seven days post-treatment, Figure 1 shows the clinical view pre-operative. Please note the 2mm localised soft tissue recession and the denuded root surface. An intrasulcular incision with two vertical releasing incisions were performed. A full flap was raised exposing the bony structure (see Figure 2).

A micromirror was used to inspect the resected buccal and palatal root (see Figure 3). The root ends were mechanically shaped using US to allow for root end filling. A micromirror was again used to control the root end cavities ready to be obturated (see Figure 4). The root end cavities were retrogradely obturated using MTA (Dentsply, www.dentsply.co.uk) (see Figure 5). The bony crypt was gently curetted and filled with calcium sulphate bony cavity (see Figure 6).

The flap was apically repositioned to cover the recession (see Figure 7). This image demonstrates the atraumatic and very tight sutures in place (6x0 monofil suture was used). The stitches were removed 48 hours after surgery. Post-surgical discomfort disappeared within 48 hours.

Figure 8 shows the excellent soft tissue healing three months post-operative (the 2mm recession was fully recovered) and the definitive full ceramic crown in place. Figure 9 shows the recall X-ray at 12 months.

Conclusion

In a survey of 1,204 endodontically treated teeth, Genet JM et al (1986) identified an incidence of 30% post-operative pain. Emergency treatments, like the type demonstrated here, were required in 57% of cases. [PD](#)

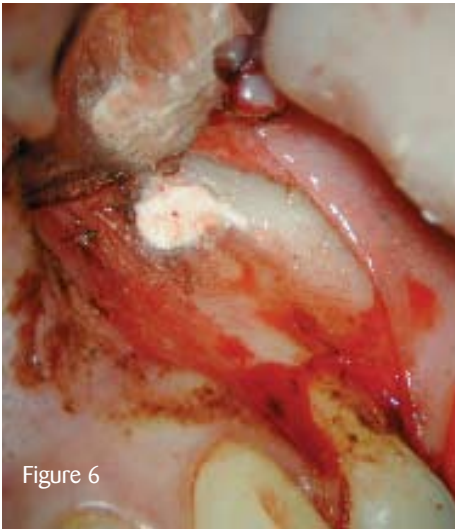


Figure 6

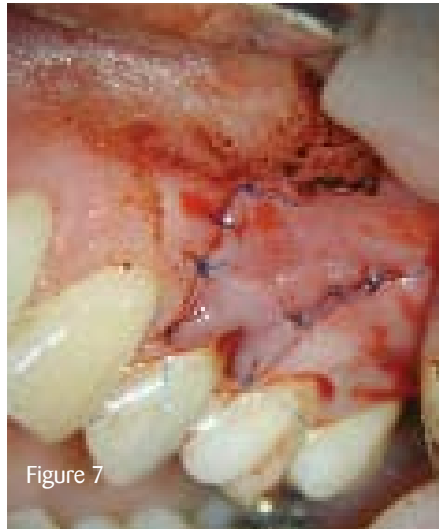

Figure 7

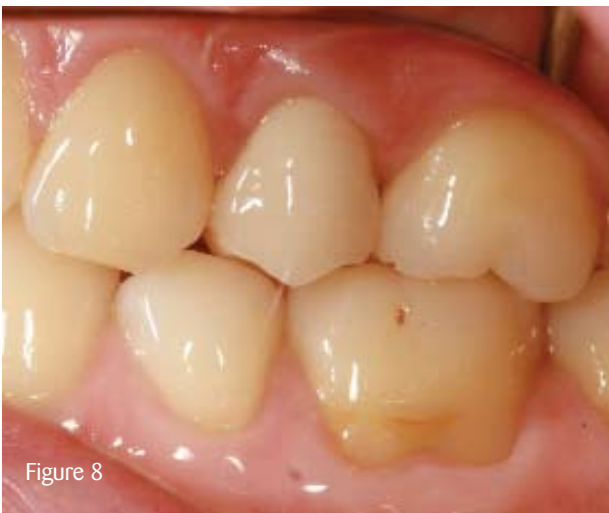

Figure 8

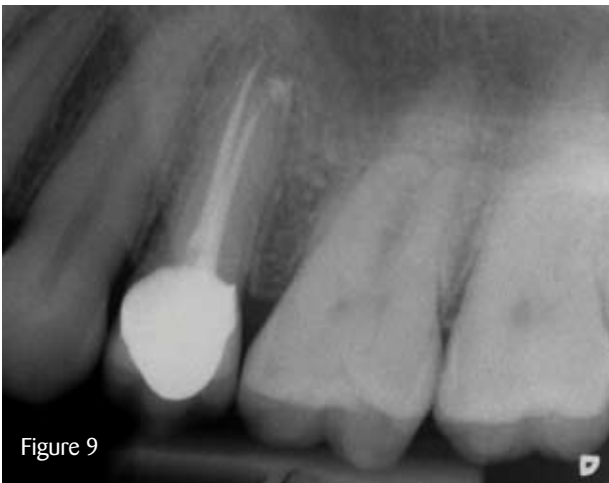

Figure 9

[Comments to pd@fmc.co.uk](mailto:pd@fmc.co.uk)

Professor Liviu Steier is visiting professor of endodontics at Tufts University, USA, and the University of Florence, Italy. He is chairman of the MSc (endodontics) programme at the University of Warwick. He has a specialist referral practice with Dr Siavash Mirfendereski in endodontics, implantology, bone management and complex prosthodontics in Wimpole Street, London. Visit www.msdentistry.co.uk for more information.