

Case of the month

November 2008

ISSUE 3



Periapical x-ray

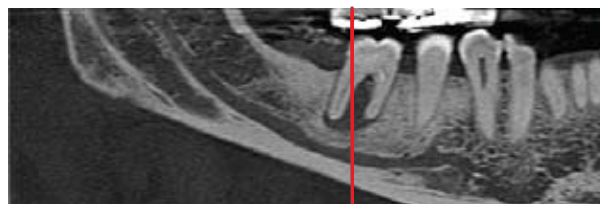Patient profile

A 56 years old male was referred for consultation and advise regarding optional RERCT of tooth 46. Periodontal probing demonstrates furcation class II. No buccal swelling, no fistula. Patient was referred to CT Dent for further diagnostic evaluation.

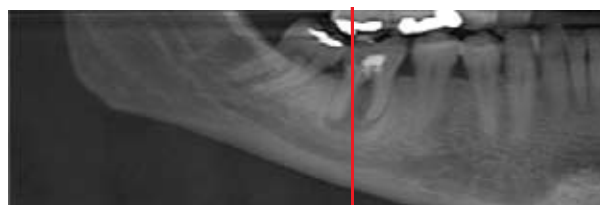
Radiography

SINGLE LOW DOSE i-CAT CBCT SCAN

Slice at mid mesio – distal distance. Image demonstrates buccal root resorption and extensive apical periodontitis.



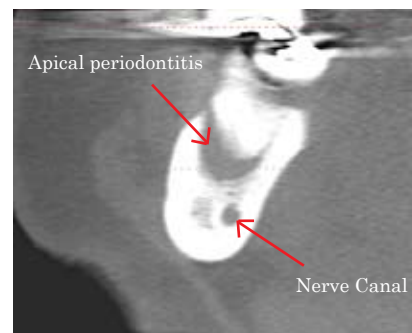
(i-CAT Vision) Panoramic view -- Slice thickness 0.25mm



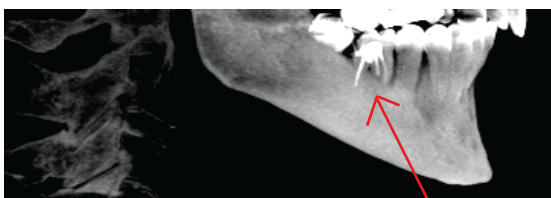
(i-CAT Vision) Panoramic view -- Slice thickness 15mm



i-CATVision 3D Image



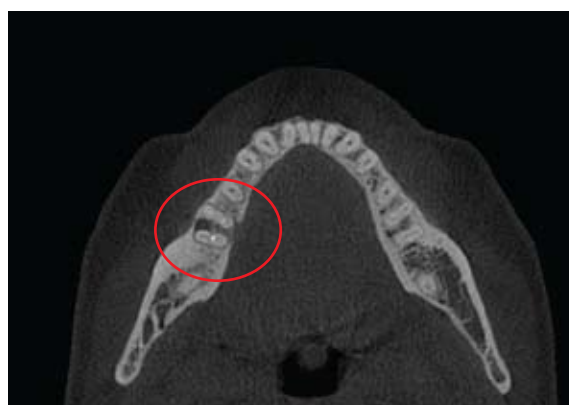(i-CAT Vision) Cross Section -- Slice thickness 0.25mm



(i-CAT Vision) Lateral view of the jaw demonstrates the definite class II furcation.

Diagnostic treatment plan

Patient was referred back to the GP for extraction.



(i-CAT Vision) Axial Slice -- Slice thickness 0.25mm



DR. MED. DENT. LIVIU STEIER
Specialist in Endodontics (GDC-UK)
Prof. Università degli Studi di Firenze
Prof. (Vis.) Tufts School of Dental Medicine
Honorary Associate Clinical Professor

20 Wimpole Street
London W1G 8GF
T +44 (0) 20- 7580 5011
www.msdentistry.co.uk
l.steier@msdentistry.co.uk

CTdent
DENTAL IMAGING CENTRE

2 Devonshire place, London, W1G 6HJ

T 020 7487 5717

F 0871 900 4315

www.ct-dent.co.uk